CAHAL
Centrum Aangeboren Hartafwijkingen
Amsterdam - Leiden

Pulmonaalklepvervanging bij Tetralogie van Fallot

- Workshop -

Dr. Bart Straver
interventie kindercardioloog & ACHD

Leids Universitair Medisch Centrum
Amsterdam UMC
Universitair Medische Centra

Programma

CAHAL
Centrum Aangeboren Hartafwijkingen
Amsterdam - Leiden

- Indicaties pulmonaalklepvervanging
- Work up: beeldvorming, ritmecontrole, functietesten
- Welk aanvullend onderzoek hebben we vooraf nodig
- Welke klep voor wie? (leeftijd, kalk, diameter, aantal OK, endocarditis
- ***Game changer:*** nieuwe zelfontplooiende klep via lies
- Afwegingen percutaan vs chirurgisch
- Toekomst

Kick-off vragen?

CAHAL
Centrum Aangeboren Hartafwijkingen
Amsterdam - Leiden

- Kent u uw hart?

- Wet van Ohm: V = I * R
  - Druk = stroom * weerstand
  - $4(V_{max}\ m/s)^2 = P_{max}$ (mmHg)

  - Drukbelasting geeft hypertrofie (verdikking)
  - Volumebelasting geeft dilatatie (verwijding)

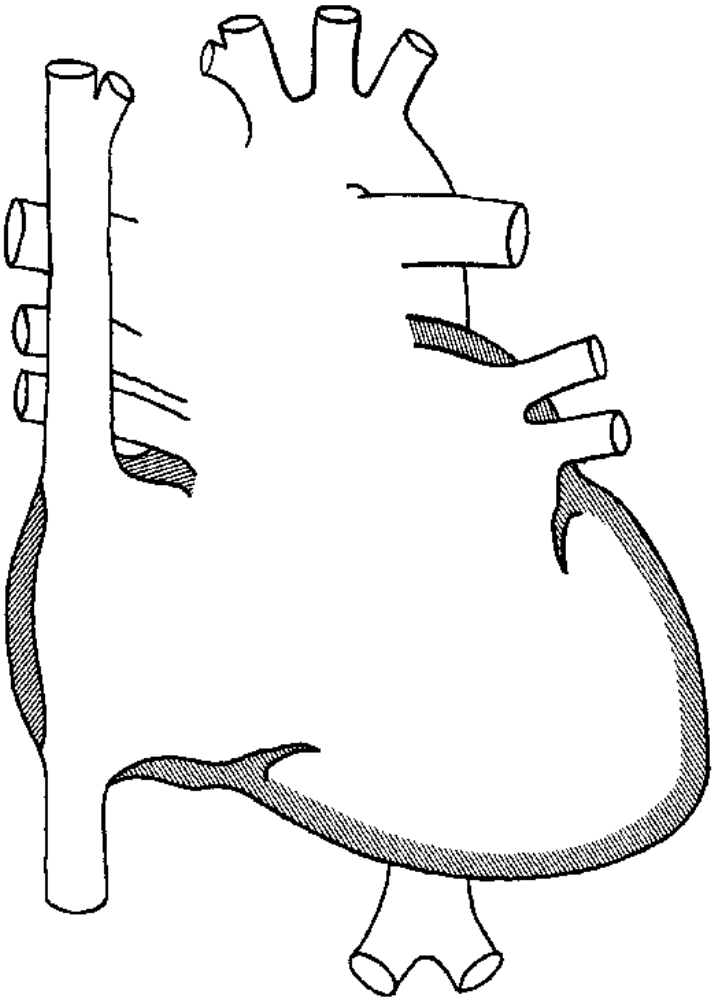

Personalized strategy

CAHAL
Centrum Aangeboren Hartafwijkingen
Amsterdam - Leiden

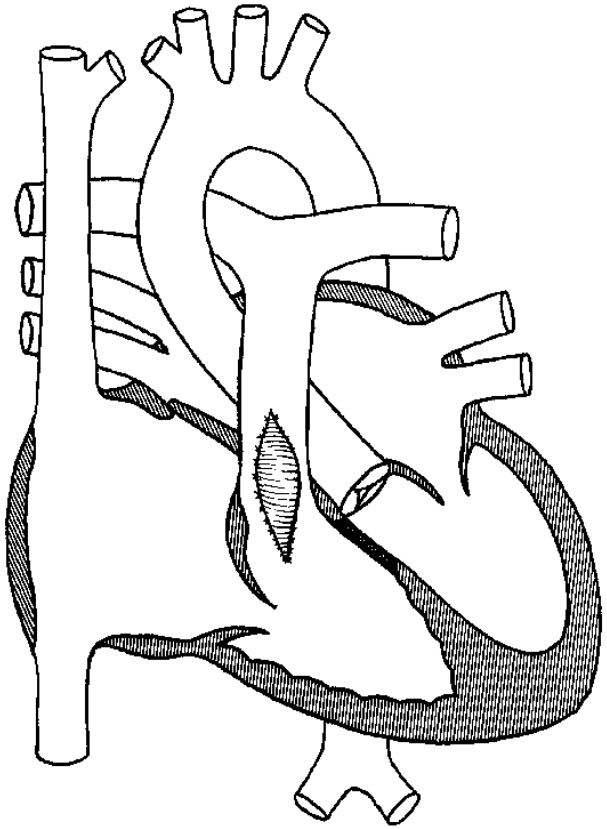

Transanulaire patch

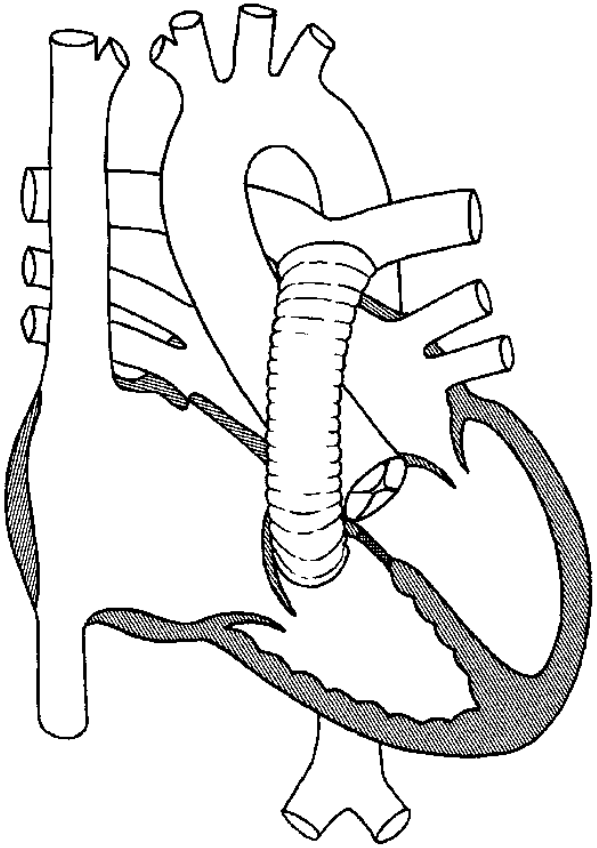

RV-PA conduit

Richtlijn 2020

CAHAL
Centrum Aangeboren Hartafwijkingen
Amsterdam - Leiden

83 pagina's

ESC
European Society of Cardiology

European Heart Journal (2020) **00**, 1–83
doi:10.1093/eurheartj/ehaa554

ESC GUIDELINES

2020 ESC Guidelines for the management of adult congenital heart disease

The Task Force for the management of adult congenital heart disease of the European Society of Cardiology (ESC)

Endorsed by: Association for European Paediatric and Congenital Cardiology (AEPC), International Society for Adult Congenital Heart Disease (ISACHD)

Mogelijke restafwijkingen…

CAHAL
Centrum Aangeboren Hartafwijkingen
Amsterdam - Leiden

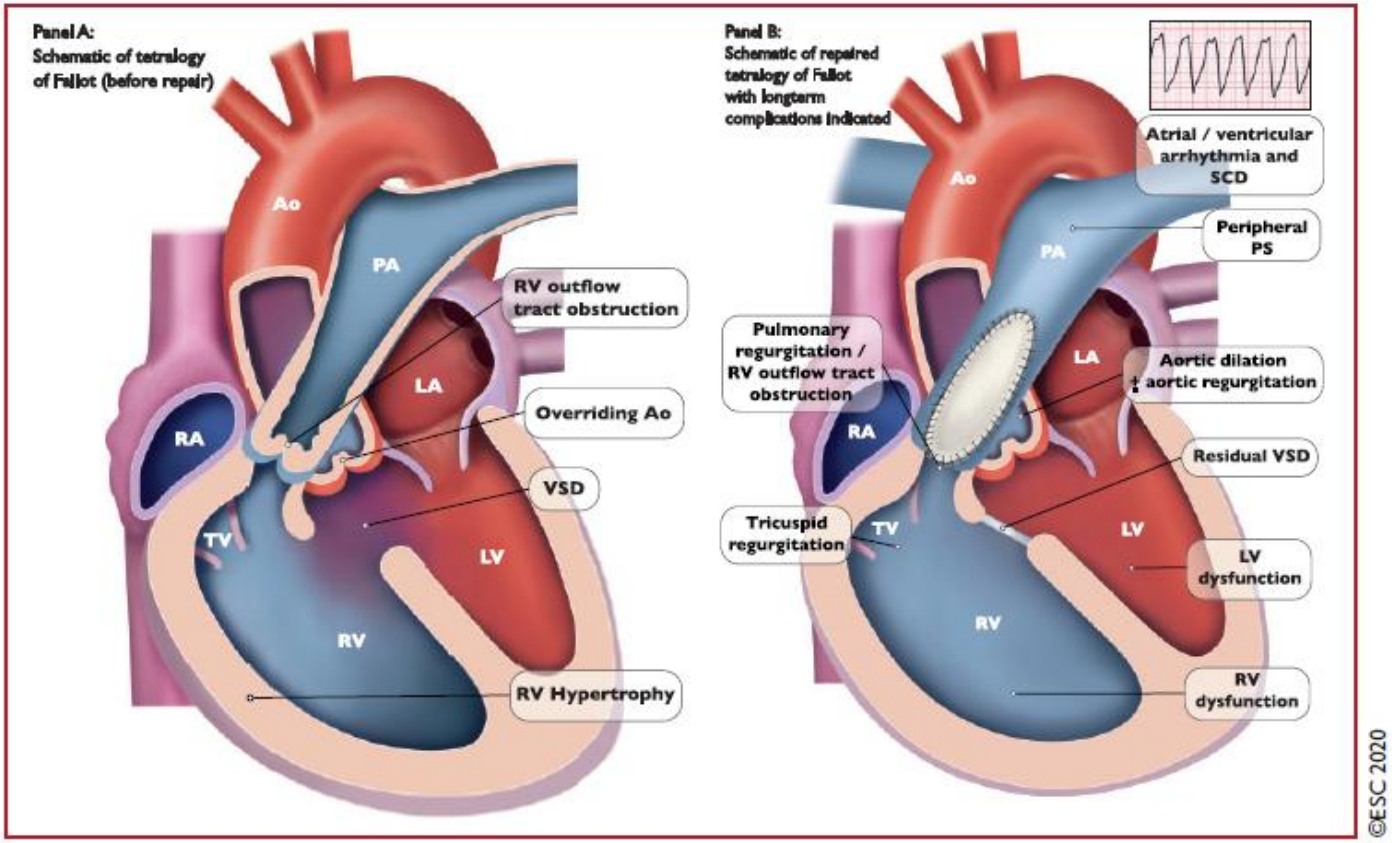

Figure 8 Management of repaired tetralogy of Fallot: long-term complications to address during follow-up.
Ao = aorta; LV = left ventricle; RV = right ventricle; PA = Pulmonary artery; TV = tricuspid valve; RA = right atrium; RV = right ventricular; LA = left atrium; PA = pulmonary artery; PS = pulmonary stenosis; SCD = sudden cardiac death; VSD = ventricular septal defect.

Stroomschema's

CAHAL
Centrum Aangeboren Hartafwijkingen
Amsterdam - Leiden

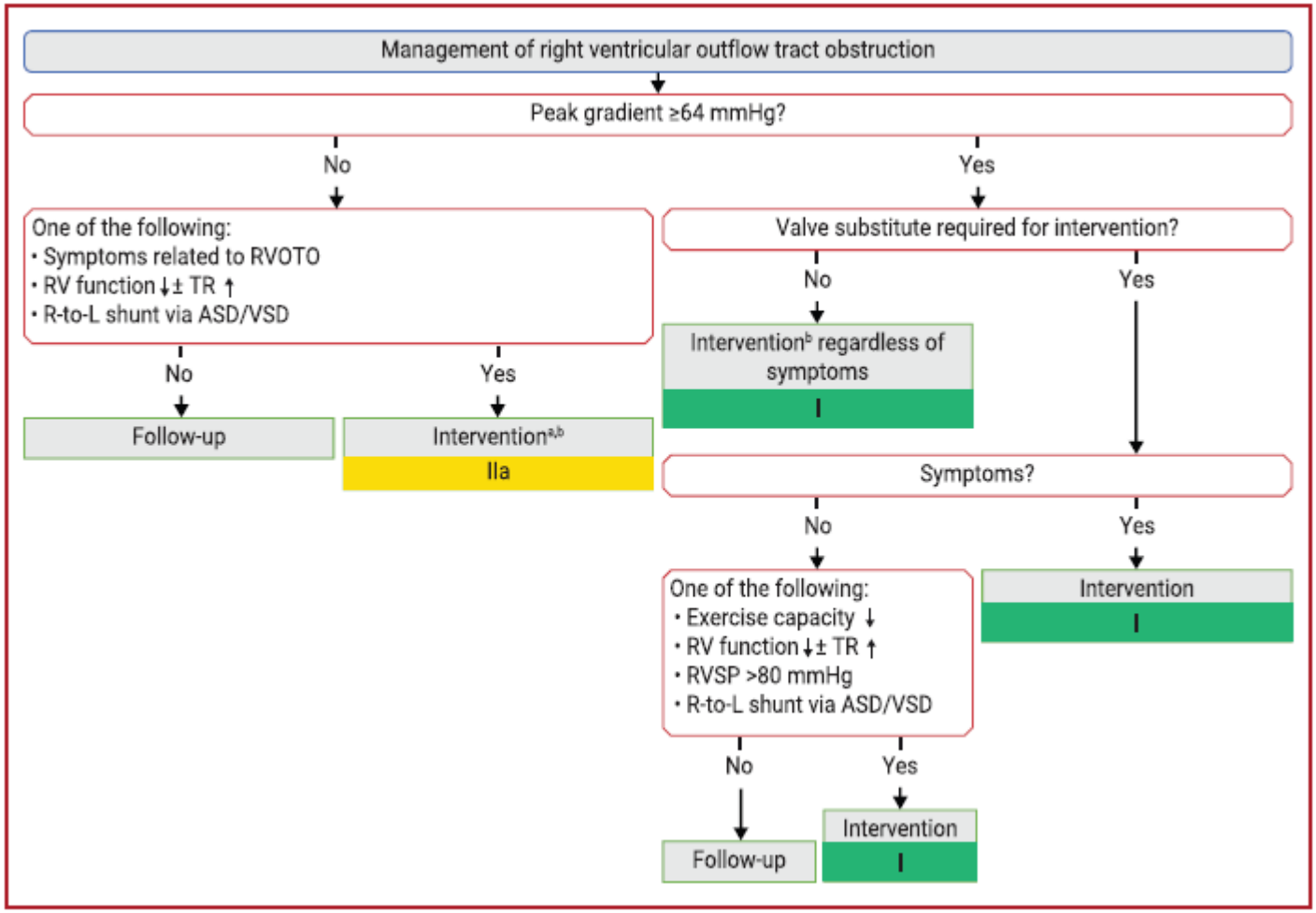

Indicaties interventie

CAHAL
Centrum Aangeboren Hartafwijkingen
Amsterdam - Leiden

Recommendations for intervention after repair of tetralogy of Fallot

Recommendations	Class[a]	Level[b]
PVRep is recommended in symptomatic patients with severe PR[c] and/or at least moderate RVOTO.[d]	I	C
In patients with no native outflow tract,[e] catheter intervention (TPVI) should be preferred if anatomically feasible.	I	C
PVRep should be considered in asymptomatic patients with severe PR and/or RVOTO when one of the following criteria is present. • Decrease in objective exercise capacity. • Progressive RV dilation to RVESVi ≥80 mL/m^2, and/or RVEDVi ≥160 mL/m^2 [f], and/or progression of TR to at least moderate. • Progressive RV systolic dysfunction. • RVOTO with RVSP >80 mmHg.	IIa	C

Personalized strategy

CAHAL
Centrum Aangeboren Hartafwijkingen
Amsterdam - Leiden

Game changer?

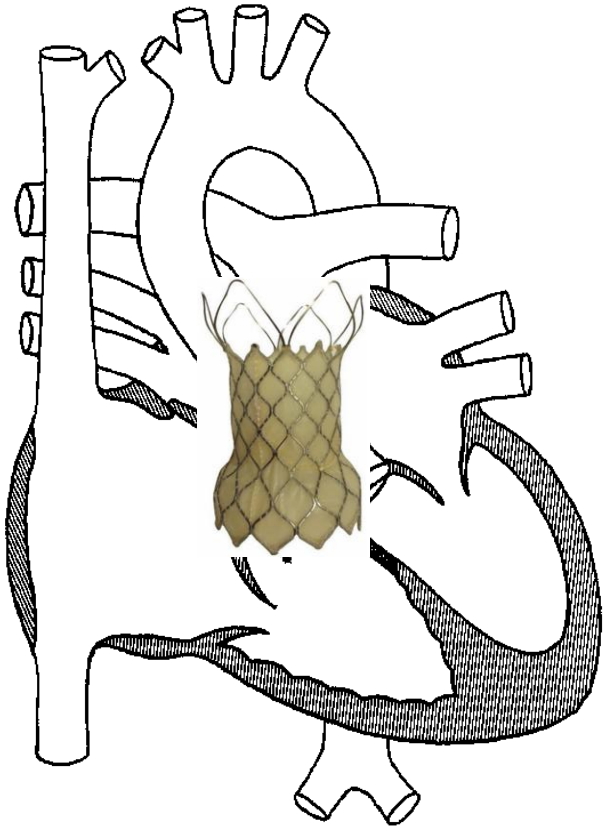

Transanulaire patch

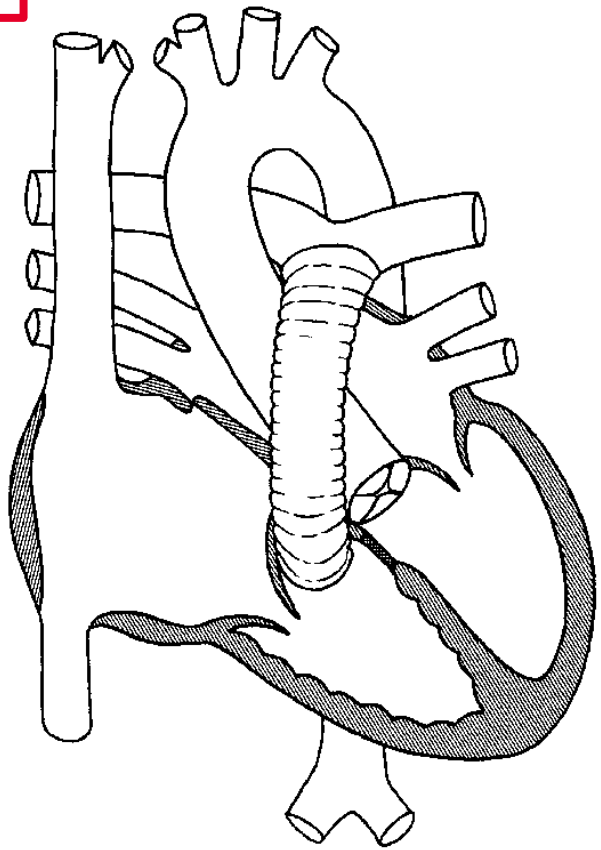

RV-PA conduit

PPVI workup route

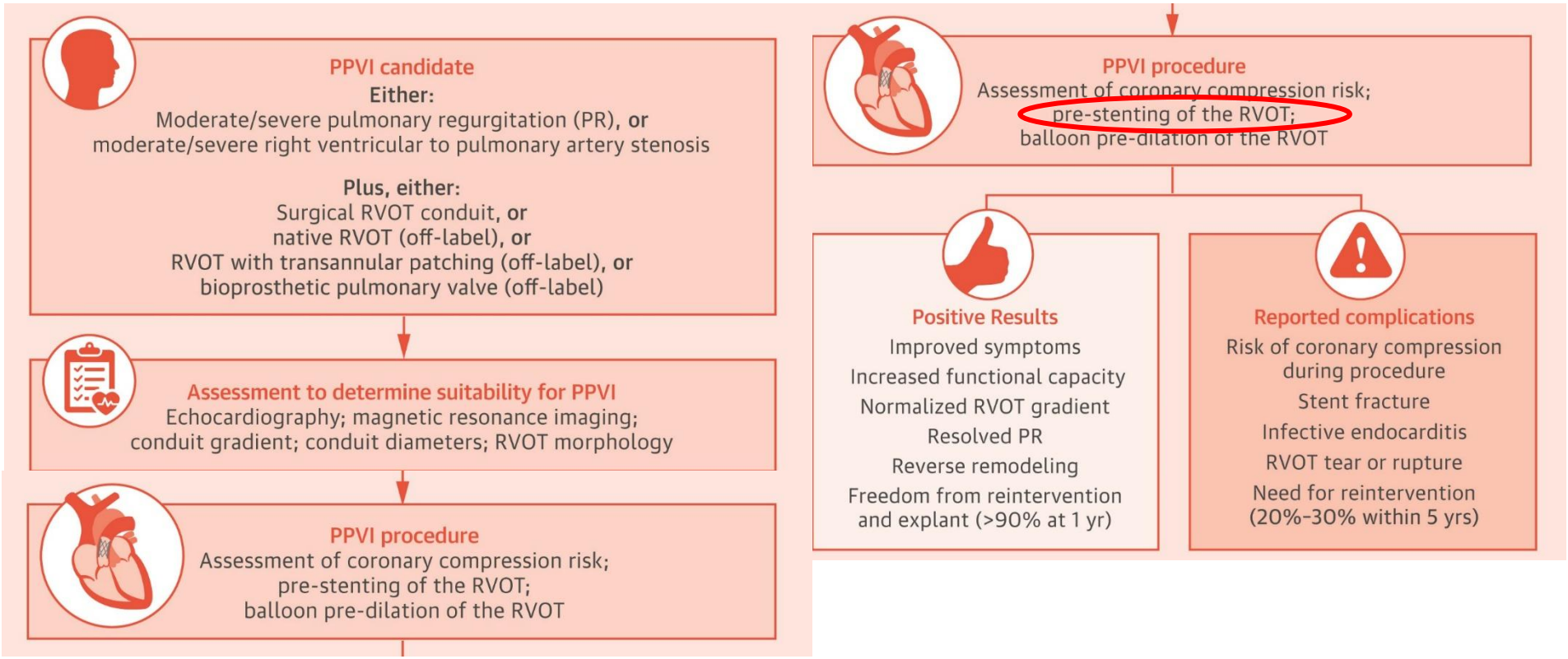

Indicaties PPVI:

CAHAL
Centrum Aangeboren Hartafwijkingen
Amsterdam - Leiden

Patient:

- Voorgeschiedenis
- Klacht: hartkloppingen / collaps
- Klacht: inspanningsvermindering
- Bekende andere hartafwijkingen
- Koorts: Endocarditis

Aanvullend Onderzoek:

- CT-scan: beoordelen anatomie en details over gepatchte RVOT.
- MRI-scan: Volume RV, Functie RV, Fibrose RVOT
- CPET / Holter: objectivering inspanning en ritme
- CT: Relatie kransslagaders met de verwachte landingszone
- Echocardiogram (TTE): gradient, mate PI, RV dilatatie, RV druk
- Historie: technische details (kleptype, diameter, gebruikte techniek)

RVOT/pulmonalis morfologie classificatie

CAHAL
Centrum Aangeboren Hartafwijkingen
Amsterdam - Leiden

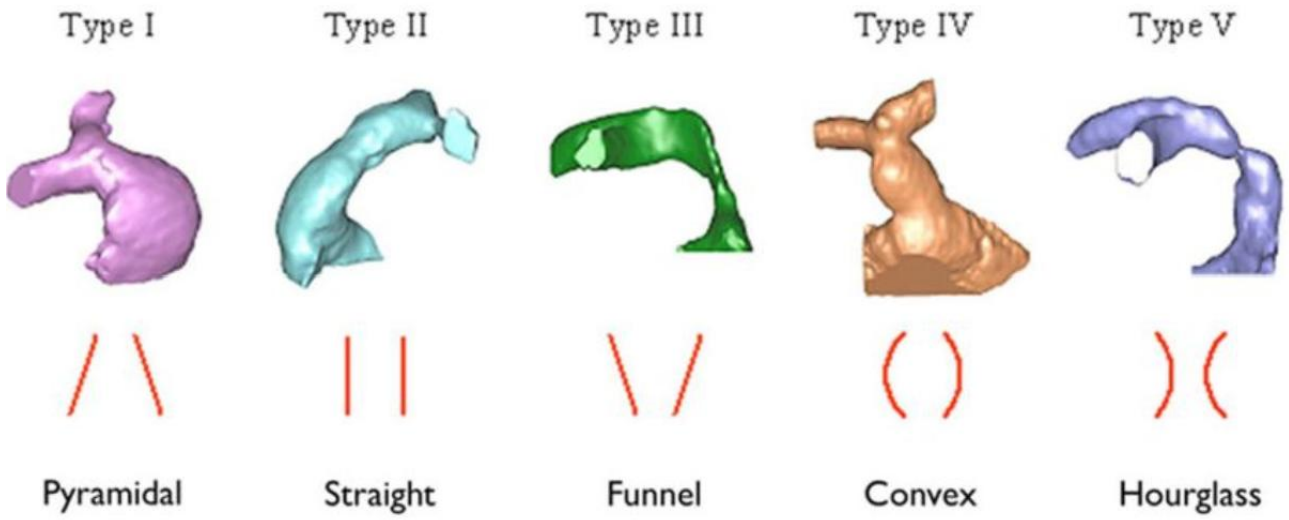

PPVI klepmaten

CAHAL
Centrum Aangeboren Hartafwijkingen
Amsterdam - Leiden

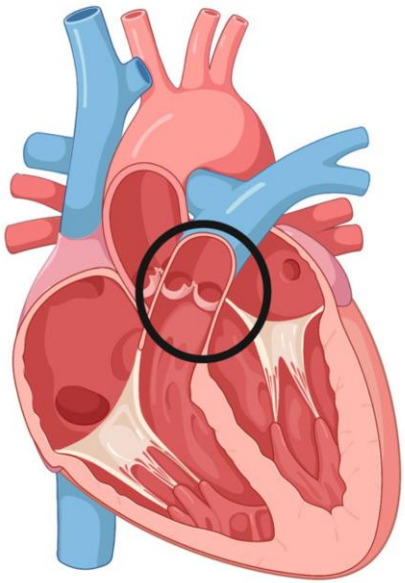

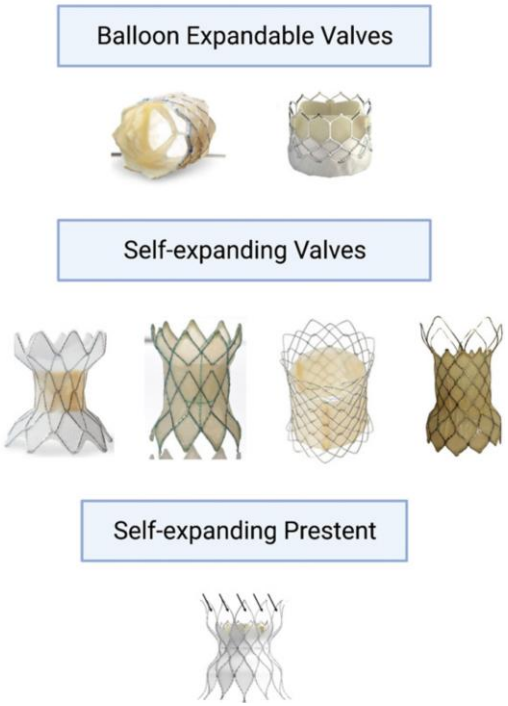

- Medtronic Melody valve:
  - 18 – 20 – 22 mm
- Edwards Sapien valve:
  - 20 – 23 – 26 – 29 mm
- Venus MedTech Venus-P:
  - 28 – 30 – 32 – 34 - 36 mm

En nu… aan het werk!

CAHAL
Centrum Aangeboren Hartafwijkingen
Amsterdam - Leiden

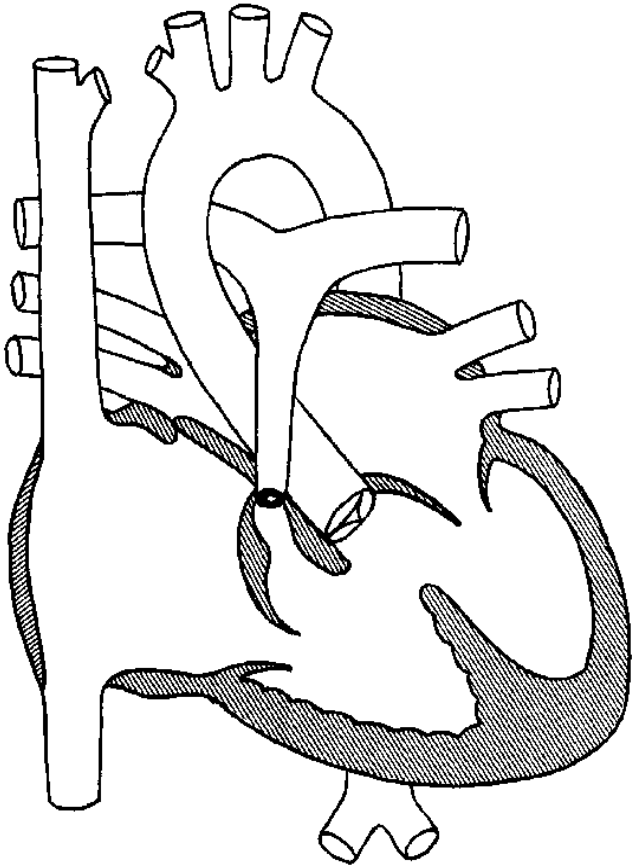

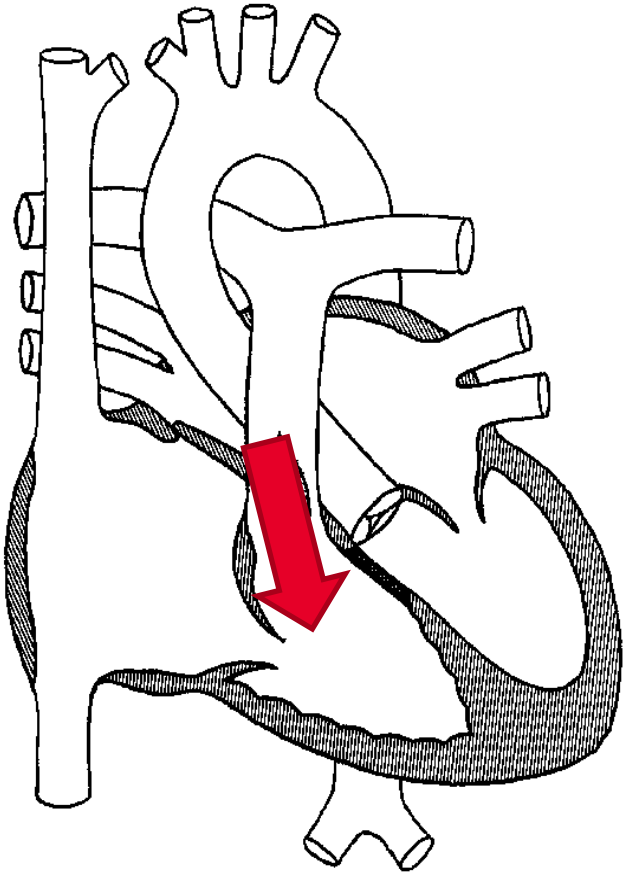

Casus 1:

CAHAL
Centrum Aangeboren Hartafwijkingen
Amsterdam - Leiden

- Vrouw, 71 jaar, Tetralogie van Fallot
- 18 jr: chirurgische correctie (details?)
- 68 jr: opname met hartfalen en boezemfibrilleren
- 70 jr: 2nd opinion → ernstige PI, gedilateerde RV met matige functie, matige LV functie
- 71 jr: langdurige opname ivm rechtszijdig hartfalen bij ernstige PI.
- Ivm verminderde RV functie en longfunctie niet aantrekkelijk voor chirurgie

- Wat te doen?

VenusP-Valve SIZE SELECTION GUIDE

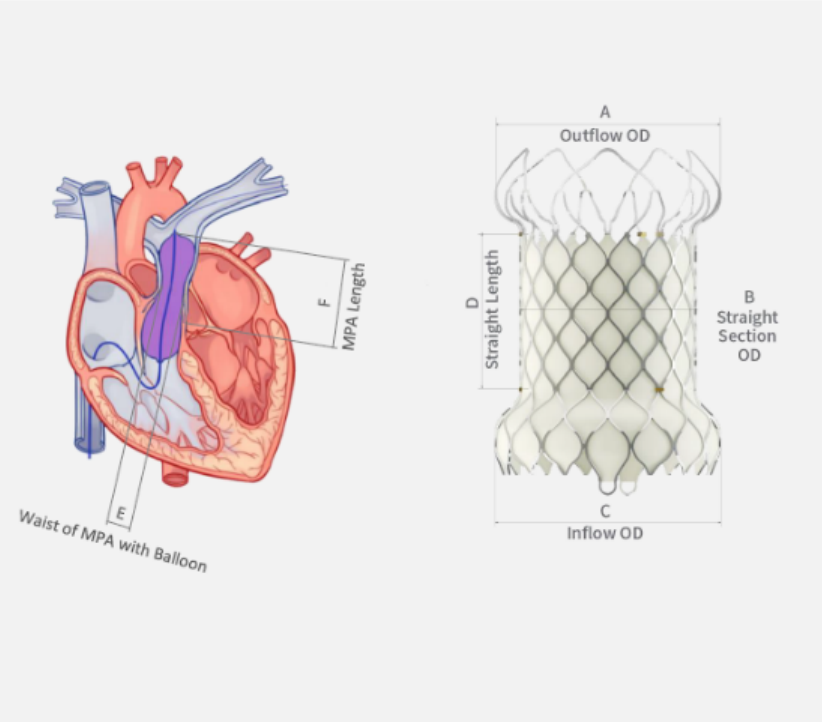

Valve Diameter

Valve Straight Section OD (B)	Waist of MPA with Balloon (E)
28 mm	24–26 mm
30 mm	26–28 mm
32 mm	28–30 mm
34 mm	30–32 mm
36 mm	32–34 mm

Valve Length

Valve Straight Length (D)	MPA Length (F)
25 mm	25-35 mm
30 mm	>35 mm

Advies klepleverancier

CAHAL
Centrum Aangeboren Hartafwijkingen
Amsterdam - Leiden

COMMENTS

- SHAPE: Tubular with likely preserved valve annulus. Mild calcification in proximal RVOT patch endocardially. Epi
- CORONARY: RCA nor clearly visualised, but left coronary system not in close approximation to RVOT
- BRANCH PA ANATOMY: unobstructed branch pulmonary arteries but both dilated.

CRANIAL CAUDAL VIEW	LATERAL VIEW
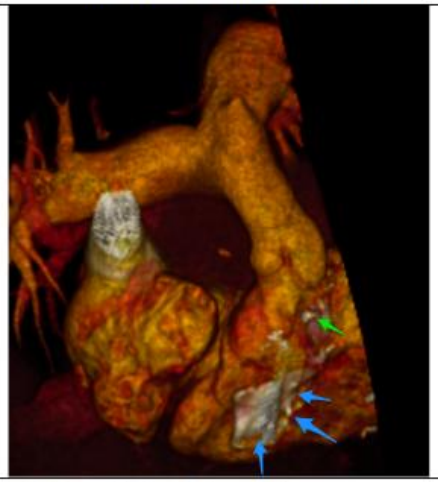	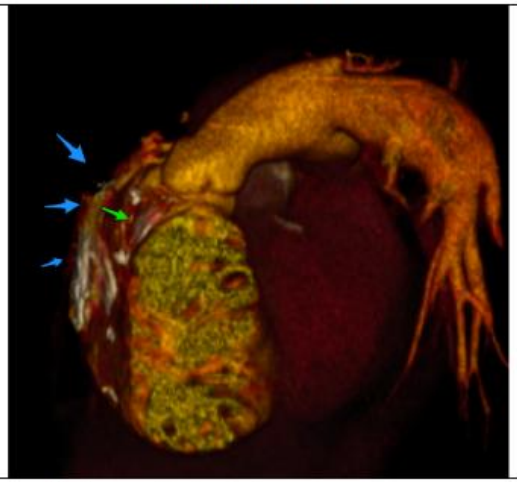
Epicardial calcium: blue arrows	Endocardial calcium: green arrow

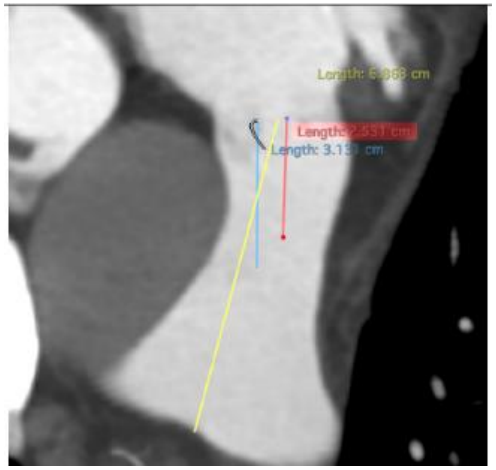

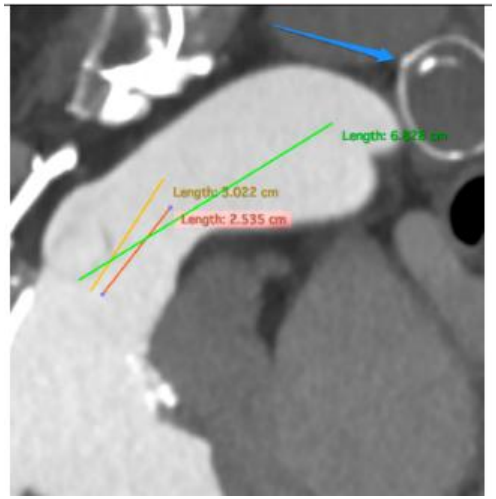

Advies klepleverancier

CAHAL
Centrum Aangeboren Hartafwijkingen
Amsterdam - Leiden

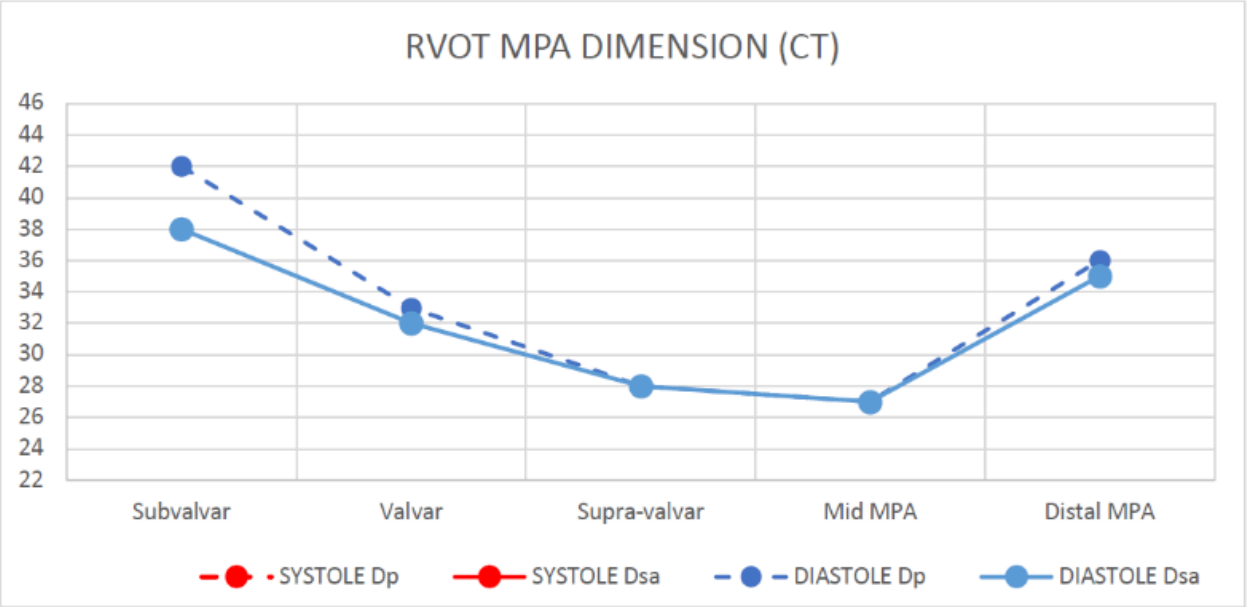

Suitable morphology, likely waist will be maintained at valvar level.
Expecting compliant mid and distal MPA
Balloon sizing to confirm final size.
Likely 34 or 36mm valves, at either length.
Long RVOT hence suitable for distal implant position with a 25mm valve if conventional landing position exceeds size range.
Favourable LPA wire position and deployment approach.
Coronary arteries to be tested at time of occlusion test.

Casus 1: ballontesting

CAHAL
Centrum Aangeboren Hartafwijkingen
Amsterdam - Leiden

Casus 1: klepontplooiing

CAHAL
Centrum Aangeboren Hartafwijkingen
Amsterdam - Leiden

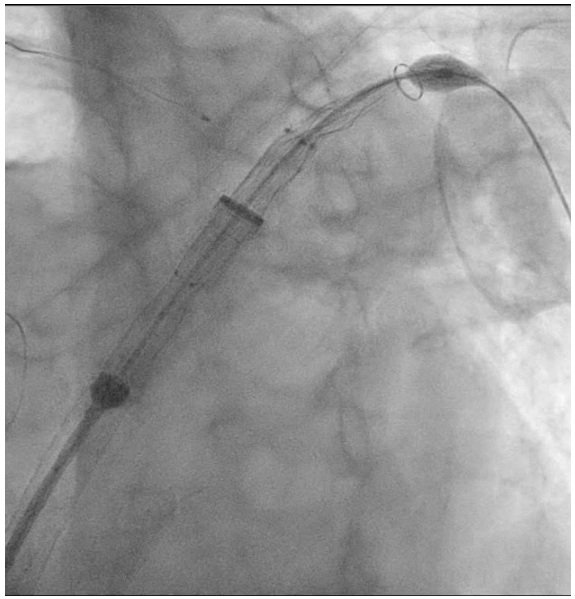
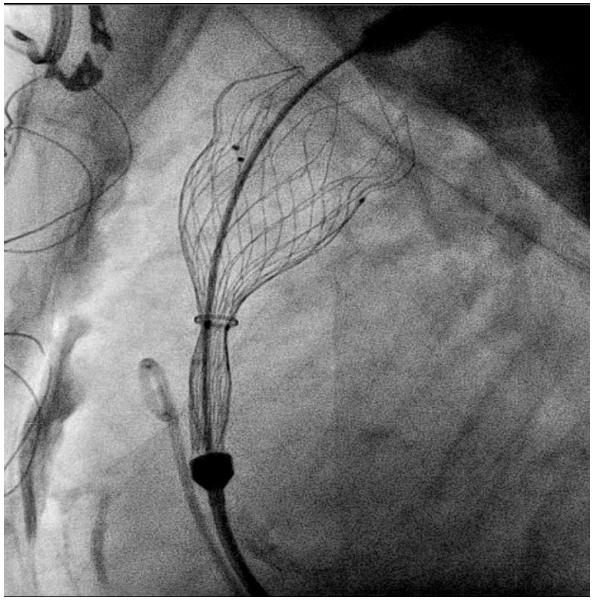
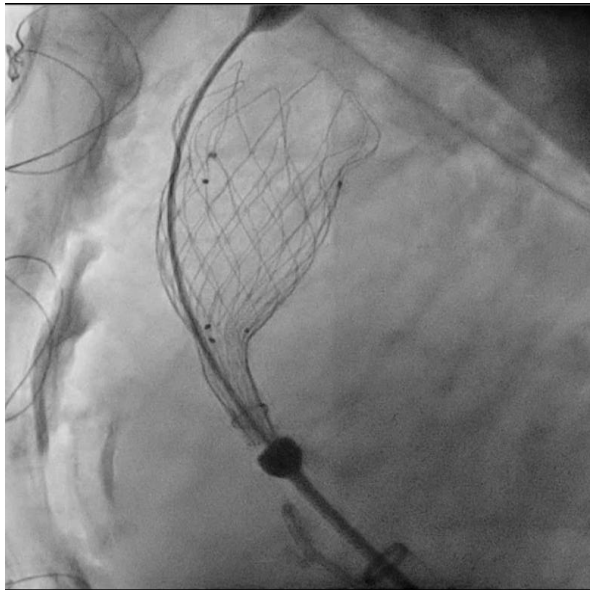

Casus 1: eindresultaat

CAHAL
Centrum Aangeboren Hartafwijkingen
Amsterdam - Leiden

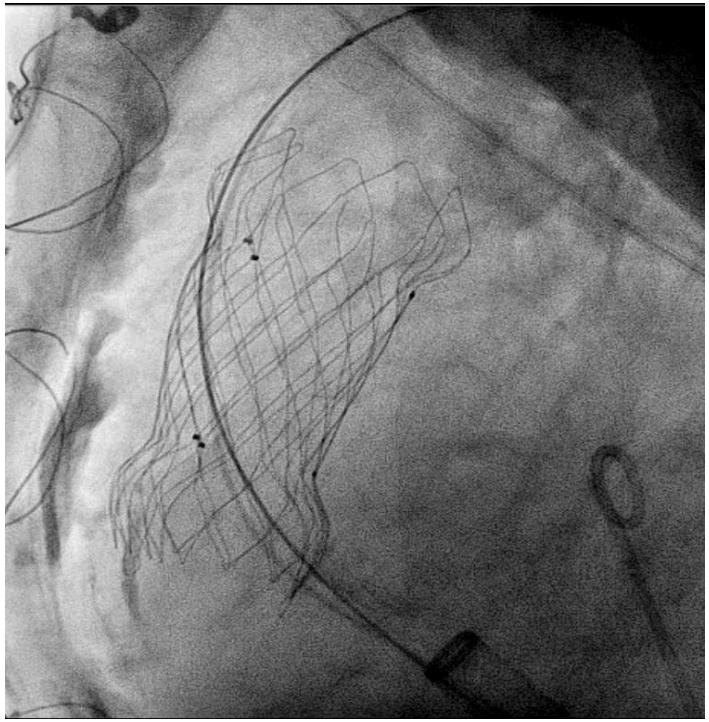

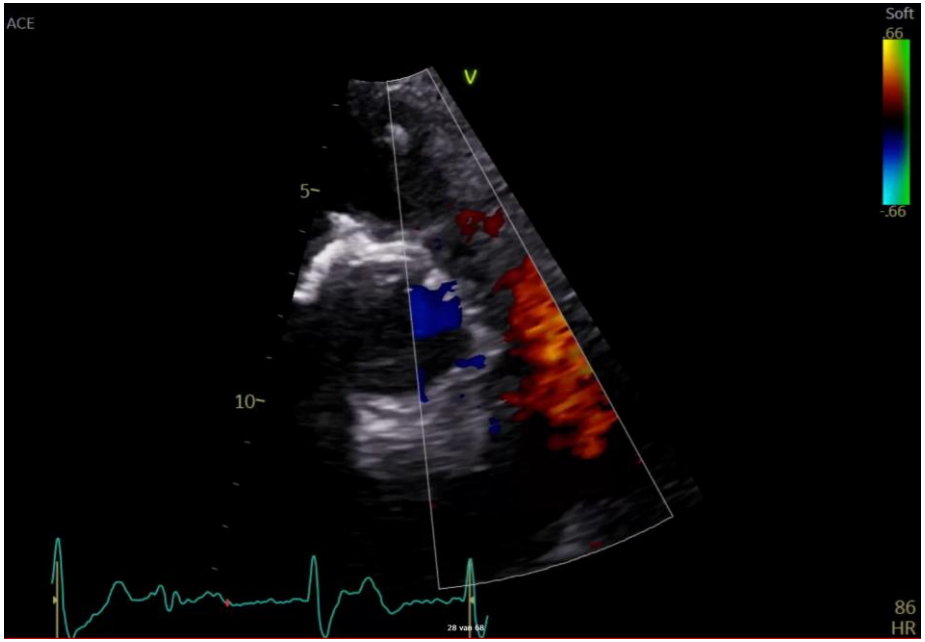

Casus 2:

CAHAL
Centrum Aangeboren Hartafwijkingen
Amsterdam - Leiden

- Vrouw, 35 jaar
- Kinderwens, verminderde inspanning
- Als kind in buitenland geopereerd
- Fallot met transanulaire patch (TAP)
- RVEDV 120 ml/m2 (matig verwijd)
- Regurgitatie Fractie 35%

- Wat te doen?

Casus 3:

CAHAL
Centrum Aangeboren Hartafwijkingen
Amsterdam - Leiden

Man, 17 jaar

6mnd: OK#1: correctie met TAP

12 jr: OK#2: Contegra 22 mm

Nu: ernstig vernauwde en verkalkte Contegra

Wat te doen?

Casus 4:

CAHAL
Centrum Aangeboren Hartafwijkingen
Amsterdam - Leiden

- Vrouw, 30 jaar
- 6mnd: OK#1: correctie met TAP
- 18 jr: OK#2: Homograft 26 mm
- -1 jr: na tandartsbezoek koorts en positieve bloedkweek: endocarditis wv AB
- Nu: Pmax 80 mmHg, moe

Wat te doen?

Interventie/chirurgie aan de pulmonalisklep

CAHAL
Centrum Aangeboren Hartafwijkingen
Amsterdam - Leiden

1. Met name bij aangeboren hartaandoeningen
2. Verschuiving van chirurgie naar interventie, hybride aanpak, shared care!
3. PPVI inmiddels ook voor geselecteerde natieve kleppen
4. Biologische prothesen, zo min mogelijk re-operaties, levenslange klep planning
5. Cave RV functie bij ernstige PI en optimale timing klepvervanging
6. Bij twijfel? Overleg met tertiair ACHD centrum in de buurt

Hartelijk dank voor uw aandacht

CAHAL
Centrum Aangeboren Hartafwijkingen
Amsterdam - Leiden